

Normally Functioning Tilting Disc Mechanical Mitral and Aortic Valve Prosthesis without Anticoagulant Therapy - An Unusual Case

Dr Shaikh Mohammed Husain¹DNB Gen Surgery, Dr Vivek Rawat²M.S,
Dr Rajkumar Yadav³.Mch

SMS Medical College and Hospital, Rajasthan University Of Health Science, Jaipur, India.

Abstract: Anticoagulation after mechanical heart valve replacement is indispensable to prevent valve thrombosis and its consequences. At the same time, excess dosing leads to complications related to bleeding. One of our patients who underwent double valve replacement for infective endocarditis lost to the follow up after 5 months of surgery then he turned back after 11 years with history of discontinuing anticoagulants. International normalised ratio (INR) was 0.97. Further evaluation revealed normally functioning mechanical mitral and aortic valve (Medtronic tilting disc).

Keywords: Mechanical heart valve, Anticoagulation, International normalised ratio

I. Introduction

Current guidelines, recommend long term Vitamin K anticoagulant (VKA) therapy for all mechanical valves (Grade 1B): target INR 2.5 for aortic (Grade 1B) and 3.0 for mitral or double valve (Grade 2C)[1]. Measurement of the prothrombin time, which is standardized by reporting the result as the international normalized ratio (INR), assesses the anticoagulant effect of VKA. We report a case of 42 year old male who had metallic double valve replacement done in 2003 for rheumatic mitral and aortic valve stenosis with infective endocarditis, discontinued taking anticoagulants after initial 5 months remained asymptomatic for 11 years and now, found normally functioning both the prosthesis confirmed by investigations.

II. Case Report

A 42 year old patient who underwent double valve replacement through mid line sternotomy in September 2003 at the age of 30, was readmitted by same surgeon in 2014 for complaint of projecting sternal wire of previously operation done 11 years back. Search of record revealed that in 2003 he was suffering from severe rheumatic aortic and mitral valve stenosis with native valve endocarditis and vegetation on aortic valve cusp. That time he underwent emergency open heart surgery with implantation of 21 size medtronic tilting disc aortic and 25 size medtronic tilting disc mitral valves prosthesis. Postoperative period was uneventful and he was discharged on acenocumalone after 2 weeks of hospital stay. He turned up only once after surgery for follow up and then discontinued all the drugs including acenocumalone 2 mg/day after 5 months of surgery. Then he never consulted any doctor for the period of 11 years and remained asymptomatic till his sternal wire started troubling him. There was no history of dyspnoea, thromboembolism, unconsciousness or transient ischemic attack during this period.

Now his clinical examination was unremarkable. Heart rate was regular at 78 beats/min and blood pressure 114/70 mmHg. Both valve clicks were clearly audible on auscultation. Blood investigations showed Haemoglobin 12.7 gm/dl, platelet count 1.81 lakhs/ml with liver and renal function values within normal limits. Bleeding and clotting time was 2.20 and 4.20 minutes respectively. Prothrombin time was 12.9 sec with control value of 13.9 sec and INR of 0.97. Electrocardiogram and Chest radiograph revealed no significant abnormality. Further cardiac evaluation with transthoracic echocardiogram showed normal left ventricular systolic and diastolic function. Mean velocity was 102 cm/sec with mean pressure gradient of 4 mmHg across the mitral valve and was 181cm/sec and 15 mmHg across the aortic valve. There was no evidence of pannus or thrombus. Normal valve excursion was seen in fluoroscopy. Patient was discharged on acenocumalone and advised to be under regular follow up and treatment with periodic monitoring of PT-INR.

III. Discussion And Conclusion

The present guidelines advice to target INR of 2.5 for aortic and 3.0 for mitral or double valve. Our patient had INR of 0.97 which was far below the recommended values and still survived asymptotically with normally functioning mechanical valves for 11 years. This lead us to look into the literature to find out the reason behind such an unusual presentation.

63 patients have been reported in literature with uncomplicated functioning of various mechanical valves in aortic or mitral positions without anticoagulation. (Table 1)[2-9]

Activation of platelet aggregation and the coagulation cascade has been noted in the early postoperative period by the raw intracardiac surfaces, sewing ring and suture knots. Bjork *et al*[3] postulated that it may require at least 3 months for these raw surfaces to be endothelialised so that anticoagulation may not be required 3 months after valve replacement. 12 patients with mechanical mitral valve replacement were followed for a period of 13 years. They received anticoagulation for 3 months after which it was discontinued and no thromboembolic events were noted.

Ozler *et al* reported a case of aortic valve replacement with Bjork-Shiley tilting disc mechanic valve who discontinued warfarin few months after surgery and survived for 26 years. Although, patient presented with valve thrombosis and dysfunction after 26 years but would not have survived with it asymptotically for such a long time[10].

Frank Edwin et al reported 2 cases in which the therapeutic target INR could not be achieved for 53.5 months in one and 16.9 months in another patient despite good compliance with oral anticoagulation and regular INR monitoring. No complication related to thromboembolism was noted during this period[11].

A similar case was reported by Kueh *et al* where the patient underwent mechanical mitral valve replacement had been inadequately anticoagulated for 2 years due to warfarin resistance and no complication occurred[12].

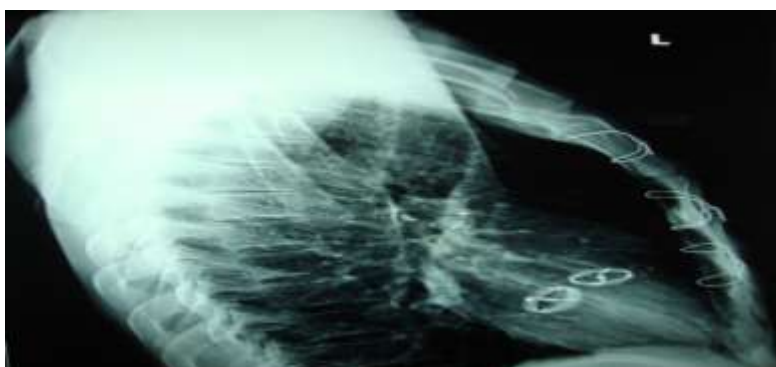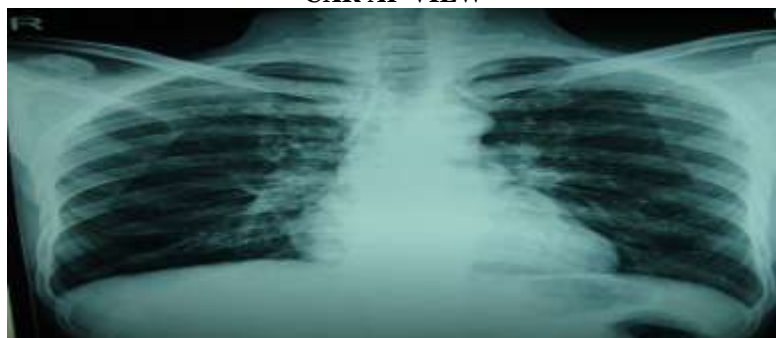
After aortic valve replacement, the risk of thromboembolic events falls from 16% per patientyear in the early postoperative period to 1.4% per patientyear at 5 years. Similarly, after mitral valve replacement, the risk falls from 21% per patientyear to 2.5% per patientyear[13].

Survival and thromboembolism appears to be more dependent upon patient related risk factors also rather than type of prosthetic valve only. Several patient related traditional and non-traditional risk factors have been reported to contribute to thromboembolic risk after valve replacement[14,15]. Patients have been seen at extreme ends of VKA related complications of thrombosis and bleeding with similar dosing and strict monitoring of INR. With minimal doses of VKA some present with massive intracranial hemorrhage and with very high dosing some present with prosthetic valve thrombosis.

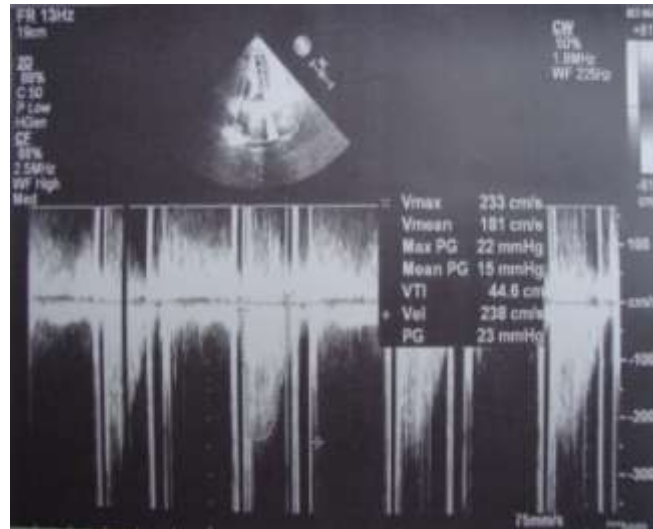
Although, it seems impossible for mechanical heart valves to be functioning normally for such a long period without anticoagulation, but examples are present in literature and even we came across such an unusual case. Potential factors remain unclear in these cases and need further study.

IV. Figures And Table

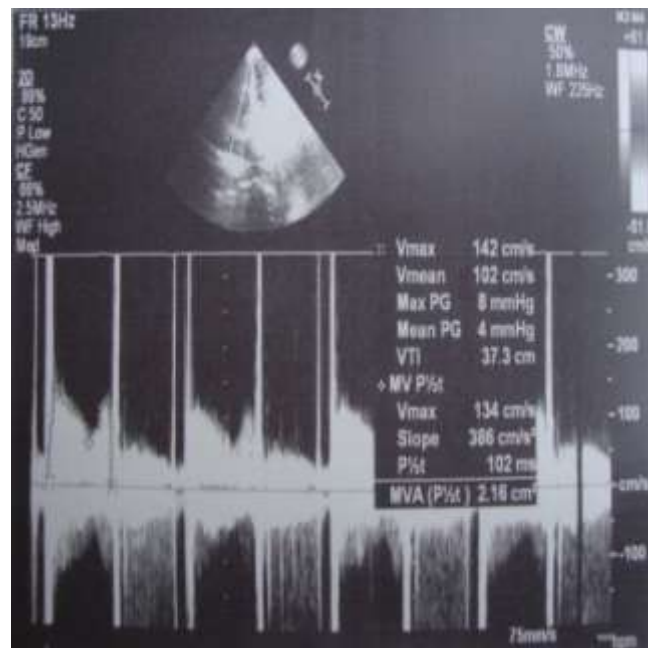
CXR AP VIEW



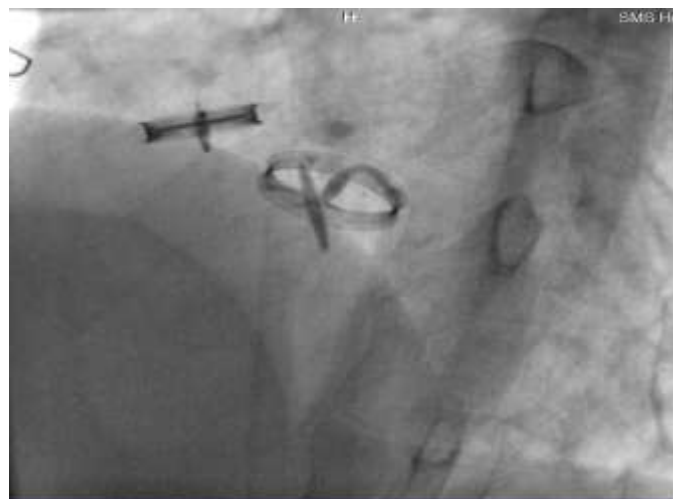Cxr Lateral View



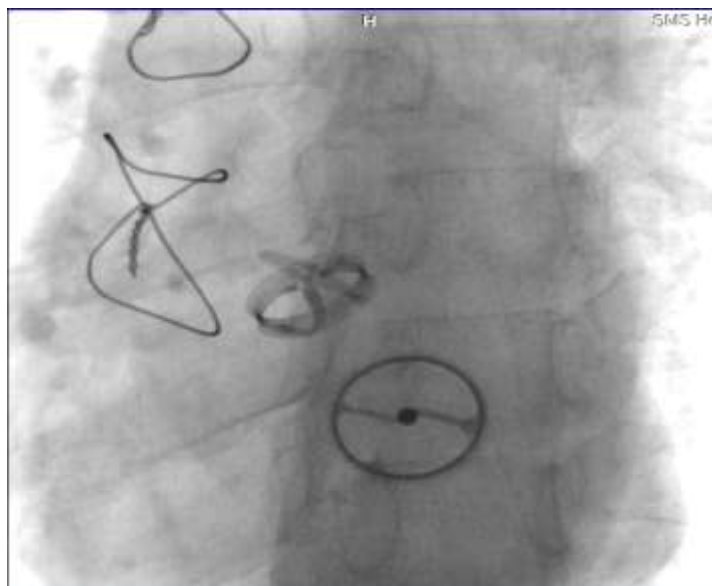
Echo 1



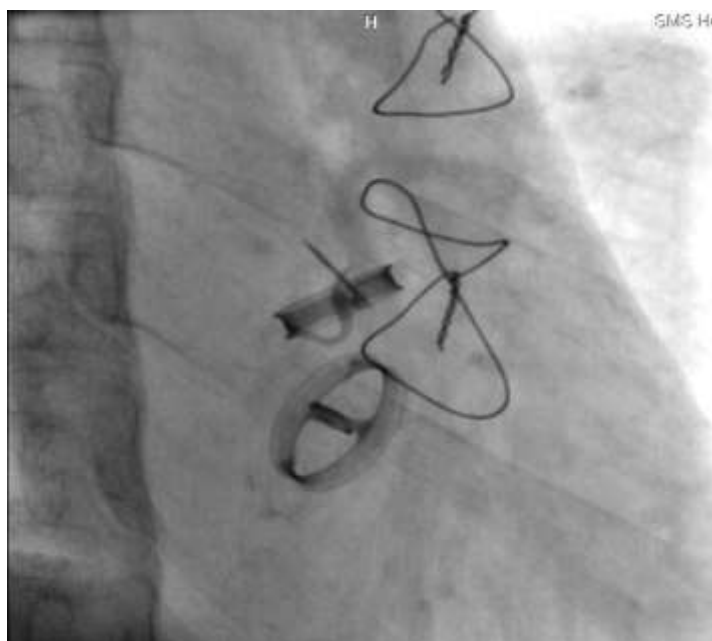
Echo 2



Fluoroscopy 1



Fluoroscopy 2



Fluoroscopy 3

Reference

- [1]. Whitlock RP, Sun JC, Frenes SE, et al. Antithrombotic and thrombolytic therapy for valvular disease: Antithrombotic Therapy and Prevention of Thrombosis, 9th ed: American College of Chest Physicians Evidence Based Clinical Practice Guidelines. Chest 2012; 141:e576S.
- [2]. Andersen VP, Alstrup P. Long-term survival and complications in patients with mechanical aortic valves without anticoagulation. Eur J Cardiothorac Surg 1992;6:62–65.
- [3]. Bjork VO, Ribeiro A, Canetti M. Mechanical mitral valves without longterm anticoagulation up-to thirteen years. J Thorac Cardiovasc Surg 1999;118:767–769.
- [4]. Uzun A, Cagil K, Ula M. Evaluation of three different cases who had mechanic heart valve replacement and surviving without anticoagulant therapy over 20 years. Turk J Thoarc Cardiovasc Surg 2001;9:247–249.
- [5]. Kuchukaksu DS, Akgul A, Uzun A, Tarcan O, Cagli K, Sener E, Tasdemir O, Bayazit K. Thirty years survival without anticoagulation after aortic valve replacement with a Bjork-Shiley prosthesis. J Heart Valve Dis 2001;10:548–549.
- [6]. Yildiz A, Ozcan F, Dogan M, Ozlu MF, Saamaz A. Twenty-two years without anticoagulation with metallic heart valve. J Natl Med Assoc 2006;98:8:1348–1349.
- [7]. Ikizler M, Birdane A, Sevin B. An old friend is still at work: 34-year-old well functioning Starr-Edwards aortic prosthesis without anticoagulation. Int J Cardiol 2007;116:e1–e3.
- [8]. Sharma S, McMurty K, Chalapathy N, et al. Mechanical aortic valve without anticoagulation for twentythree years. Interact Cardiovasc Thorac Surg 2009; 8: 263–5 [PubMed]

- [9]. Gul EE, Altunbas G, Kayrak M, Ozdemir K. The end of good luck"--long-term survival without anticoagulation: a case report and review of the literature. *Clin Appl Thromb Hemost*. 2012; 18(2):222-4.
- [10]. A Ozler, M Dumantepe, A Tarhan, K Atalan, T Denizalt. Mechanical Aortic Valve Without Anticoagulation For Twenty Six Years. *The Internet Journal of Thoracic and Cardiovascular Surgery*. 2013 Volume 16 Number 1.
- [11]. Edwin F, Tettey MM, Aniteye E, et al. Freedom from thromboembolism despite prolonged inadequate anticoagulation. *BMJ Case Reports*. 2009;2009:bcr07.2009.2066. doi:10.1136/bcr.07.2009.2066.
- [12]. Kuey YK, Ee BK, Teoh PC. Resistance to oral anticoagulant therapy – Case report and review of literature. *Singapore Med J* 1982; 24: 114–5
- [13]. Butchart EG, Lewis PA, Bethel JA, et al. Adjusting anticoagulation to prosthesis thrombogenicity and patient risk factors. *Circulation*. 1991; 84(suppl III):61–69.
- [14]. Butchart EG, Ionescu A, Payne N, Giddings J, Grunkemeier GL, Fraser AG. A New Scoring System to Determine Thromboembolic Risk After Heart Valve Replacement. *Circulation*. 2003;108[suppl II]:II-68-II-74.
- [15]. Emery RW, Emery AM, Raikar GV, et al. Anticoagulation for mechanical heart valves: a role for patient based therapy. *J Thromb Thrombolysis* 2008;